

# A Comprehensive Literature Review on the Architecture of the Upper Labial Frena

S SURRAJ<sup>1</sup>, L DAISY<sup>2</sup>, D SUSHMA<sup>3</sup>, C MRUDULA<sup>4</sup>, P RAO SUSHMA<sup>5</sup>

## ABSTRACT

Over the past few years, various surgical procedures have evolved that focus on releasing the taut superior labial frena in infants, yet little is known about their normal or variant morphology despite the growing incidence of severe upper labial frenar tie. Apart from this, the role played by distorted upper labial frena in uncomfortable latching or problems in breast feeding has been a major concern among mothers thereby significantly affecting public health. Hence, the purpose of this literature review is to lucidly highlight the various existing grading schemes and classification systems in literature for superior labial frena and also to understand their precise morphology and developmental origins that will be of great help to oral surgeons and plastic surgeons in performing release repair or reconstructions for the upper lip tie.

**Keywords:** Alveoli, Frena, Grade, Morphology, Vestibule

## INTRODUCTION

Most of the surgical procedures involving the oral frena, focused on the release or repair of the lingual frenum rather than its labial counterpart due to the impetus given to the tongue-tie or ankyloglossia that causes difficulties in infant feeding and altered speech production as opposed to the lip-tie that was considered to play a weak role in problems related infant feeding for a long period of time [1]. It was only later that a few studies began focusing on their role in causing latching problems, feeding difficulties and also for their involvement in diastema formation and gingival recession [2,3]. Still, labial release or repair procedures are in their naïve stages of growth owing to the fact that the functional anatomy and morphology of labial frena has always been less understood due to the paucity of randomised controlled trials and larger cohort studies focusing on their mechanisms of involvement in distorted states [3-5].

It was later found that the taut upper labial frena has a more definitive role in causing diastema between the upper incisors, upper gingival recession, latching and feeding difficulties in neonates and infants when compared to the lower labial frena which apart from causing gingival recession had hardly any role in causing feeding difficulties to mothers or latching difficulties to infants [4-7]. Hence, this literature review focuses on the architecture and patterns of the superior labial frena alone, and not the lower labial one. Classification schemes were proposed for the upper labial frena but each with a different version that lacked clarity especially with regard to their grading pattern in upper lip tie [1,2]. Their morphometric architecture and histological composition also lack clarity, as their development.

## MORPHOLOGY AND INTERNAL STRUCTURE OF THE UPPER LABIAL FRENA

According to Henry SW et al., the superior labial frenum is a fold of soft connective tissue that attaches the upper lip to the anterior surface of the maxillary gingiva and it originates from the midline of the undersurface of the lip [8]. However, Edwards JG had a contrary opinion to that of Henry SW et al., and postulated that it is exclusively made of alveolar mucosa that arises embryologically as a posteruptive remnant of tecto-labial bands [9]. There is a discrepancy in histological findings of maxillary frena among various workers [Table/Fig-1]. As per reports of Henry SW et al., done on

biopsied and autopsied frena, the internal structure of the upper labial frenum was made of loose connective tissue and elastic fibers and no muscle fibers were spotted [8]. However, Gartner LP and Schein D, had a contrary view to that of Henry SW et al., and had found in their study that the upper labial frenum was composed only of alveolar epithelial tissue and striated muscle fibres and did not contain any elastic fibers [10]. Moore KL, denote the upper maxillary frenum only as a fibrous collagenous tissue [11], whereas Gartner LP and Schein D, and Ross RO et al., have described the upper labial frenum to consist primarily of dense connective tissue and alveolar epithelium with absence of striated muscle fibres [10,12]. The findings given by the above authors are only derived from observational studies. Definite conclusions regarding the morphology and internal structure of upper labial frena can only be drawn from large randomised controlled trials, that are lacking. This is of vital importance to guide the surgeons in microsurgical resections of the upper labial frena.

S. No.	Histological component	Henry SW et al., [8]	Gartner LP and Schein D, [10]	Moore KL, [11]	Ross RO et al., [12]
1	Loose connective tissue	+	-	-	-
2	Dense connective tissue	-	+	+	+
3	Striated muscle fibers	-	+	-	-
4	Alveolar mucosal epithelium	-	+	-	+
5	Elastic fibers	+	-	-	-

[Table/Fig-1]: Histologic features of upper labial frena.

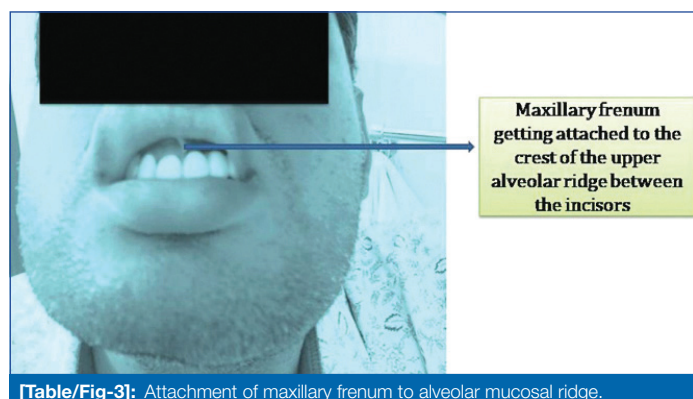
## ATTACHMENTS, CLASSIFICATION AND GRADING OF UPPER LABIAL FRENA

The maxillary frena or upper labial frena connect the undersurface of the upper lip to the midline upper gingival [2]. But this statement is quite vague because the insertion sites for the upper labial frena are diverse. Most of the frena from diverse studies [2,4,5,13-16], were seen to insert on to the palatal mucosa of the upper alveolar ridge [Table/Fig-2,3], followed by the ones that inserted on to the inferior margin at the alveolar papilla and even passing beyond to the posterior surface. The remainder were scattered at various other insertion points as depicted in [Table/Fig-2]. This shows that upper labial frenal insertions cannot be typed or patterned into specific set insertion points, rather a wide

Authors	Flinck A et al., [13]	Santa Maria C et al., [2]	Boutsi EA and Tatakis DN, [4]	Bergese F [14]	Jańczuk Z and Banach J, [15]	Placek M et al., [16]	Iwanaga J et al., [5]
Type of study	Prospective cohort	Cross-sectional	Cross-sectional	Cross-sectional	Cross-sectional	Cross-sectional	Observational study on fresh frozen cadaveric heads
Number of subjects	1021	100	226	428	1542	463	17
Age range of subjects (years)	Newborns	Newborns	1 -18	9-12	15-17	15-40	67-99 (at the time of death)
<b>Insertion point from the upper lip</b>	<b>Frequency (%) of insertion point from the upper lip among subjects</b>						
Crest of upper alveolar ridge	76.7						
Buccal mucosa of upper alveolar ridge	6.7						98
Palatal mucosa of upper alveolar ridge	16.7		10.2	4.8	39	46.5	
At attached Gingival margin		83		58.2	36		
Near the mucogingival junction		6		12.6			2
Along the inferior margin at the alveolar papilla and beyond to the posterior surface		11	48.2		5	19.2	
Alveolar mucosa				5.5	20		
Sulcus of free gingiva				10.5		34.3	
Free gingiva			41.6	7.1			

**[Table/Fig-2]:** Vivid attachments of upper labial frena from the undersurface of median upper lip [2,4,5,13-16].

range of insertion points need to be considered by the surgeons while removing or repairing them [13-16]. Mirko P et al., had proposed a basic classification of maxillary frena depending upon the extension of attachment of its fibers to the oral vestibular components as follows: 1) Mucosal-when the frenal fibers are attached up to muco-gingival junction; 2) Gingival-when fibres are inserted within attached gingiva; 3) Papillary-when fibres are extending into inter-dental papilla; and 4) Papillary penetrating- when the frenal fibers cross the alveolar process and extend up to palatine papilla [17]. This classification still holds good and is used as a basic scheme for all other higher grading systems, however it does not take into account the other insertion points as shown in [Table/Fig-2] [2,4,5,13-16].



**[Table/Fig-3]:** Attachment of maxillary frenum to alveolar mucosal ridge.

Kakodkar PV et al., had also reported certain extra variants of maxillary frena, in addition to that of Mirko P et al. They are-simple frenum with a nodule, simple frenum with appendix, simple frenum with nichum, bifid labial frenum, persistent tecto-labial frenum, double frenum and wider frenum [17,18]. This system only holds good if these variants of frena are found in that particular population and cannot be generalised to a wider group. Moreover, this system [18] failed to elaborate upon the insertion points of frena hence this system was refuted by many workers. Another grading system for the superior labial frena, was the one proposed by Kotlow LA, who categorised them into four grades based on clinical observations on neonatal oral vestibuli, as follows- grade 1: minimal alveolar mucosa and minimal attachment; grade 2: the frenum attaches primarily into gingival tissue, at the junction point of the free and attached gingival margins; grade 3: the frenum inserts just in front of the anterior papilla and grade 4: the frenum attaches just into the anterior papilla and extends into the hard palate [1]. The authors of this classification system proposed that the severity of a "lip-tie"

increased with higher grades and this also increased the chances of problems related to breastfeeding. However, this classification cannot be deemed accurate as it doesn't use any anatomical fixed landmarks. Though this system of classification states that the severity of lip-tie has been used as a clinical factor in the decision for tie release, it still failed to establish a relationship between the grade of lip-tie and breastfeeding difficulty nor were the clinical outcomes after lip-tie release clearly demonstrated. Another important fallacy in this system is that Kotlow LA, tried to standardise this grade for the entire age groups of individuals just by considering the appearance of neonatal upper labial frena [1].

The next modified classification was the stanford classification system proposed by Santa Maria C et al., where they combined grades 2 and 3 from Kotlow's scale. It is as follows- Type 1: insertion of the frenulum is near the mucogingival junction. Type 2: insertion is along the mid attached gingiva. Type 3: insertion is along inferior margin at the alveolar papilla, and can continue to the posterior surface [2]. As per Santa Maria C et al., type 1 of their classification is equivalent to grade 1 of Kotlow LA; type 2 combines grades 2 and 3 of Kotlow LA; and type 3 is equivalent to Kotlow LA grade 4 [2]. This rating system provided a more clinically meaningful distinction between different types of superior labial frena, however this system also failed to use fixed anatomical landmarks. The advantages of this rating system over that of Kotlow LA is the ease of clinical assessment in a "lip-tie" [2].

One particular study by Ray S et al., contradicts the above mentioned insertion points by various workers [3]. This is the only such study, which does not consider the inner median surface of upper lip as a fixed attachment point, but instead takes into account two mobile measurable points of attachment per frenum along with their collaborative dimensional measurements [3]. According to Ray S et al., the drawbacks with the above mentioned systems, is that the insertion points of the frena into the gingiva were described with non specific anatomic locations and without measurements of frenum insertions relative to gingival and alveolar edge landmarks. Furthermore, they argue that neither of the above studies except their own study, assessed the frenum length or thickness either separately or together, which may play a contributive role to frenum tethering and those studies also did not assess the potential association of the maxillary labial frenum with ankyloglossia [3]. The justification given by Ray S et al., in their prospective cohort study for utilising two mobile points for measuring the maxillary frenum caliber is that 'tethering' takes place

in a taut maxillary frenum of a tied lip that affects the architecture of the lip and the frenum simultaneously, hence the measurement of only one insertion point neglecting the lip contour measurements will produce erroneous results [3]. They have also refuted the classification patterns of Kotlow LA and Santa Maria C et al., which according to them are biased and based on the assumption that all upper labial frena fixedly arise from the undersurface of the inner central upper lip [3].

## CLINICAL INDICATORS OF PATHOGENIC UPPER LABIAL FRENA

As per Anubha N et al., the best way to detect an abnormal or aberrant frena for its pathological nature is by applying tension over it to check for the movement of its papillary tip or blanching produced due to compromised blood flow to that region [19]. The frena that penetrate the papillae are considered to produce more discomfort and are found to be associated with slow regression of papillae, recession, diastema, difficulty in brushing, teeth disarray and it may also impede the fitting of dentures [19]. A frenum is thought to be pathological if lip movements are disturbed and if its taut nature pulls the gingival margin away from the tooth, or if the tissue prevents a diastema closure during surgical interventions [20]. Lindsey D et al., had observed in their study that the response of frena to blanching and lip pull decreased from childhood to adult life and hence cannot be used as reliable indicators for testing the pathogenic nature of papillary frena [21], which contradicted the findings of Anubha N et al., [19]. However, the above findings are derived only from cross-sectional studies. For standardising the clinical indicators to describe the pathological role of maxillary frena, larger randomised controlled trials are necessary that are yet lacking.

## DEVELOPMENT OF UPPER LABIAL FRENUM AND ITS AGE CHANGES

The intrauterine development of the upper labial frenum, starts at the tenth week of gestation, by the formation of tecto-labial plates resembling bands that extend from the inner lip and span across the alveolar ridge for insertion into the palatine papilla [11,22,23]. This process fastens in the third, fourth and fifth months of intrauterine life and steadies down by the ninth month. By the end of the ninth month, the well formed halves of the alveolar ridges unite, thereby enclosing some portions of these tecto-labial bands into them resulting in the formation of the palatine papilla and the upper labial frenum [21-23]. After birth, the alveolar process formed by the union of alveolar ridges slowly starts moving in an apical direction from a coronal plane [11,23]. This apical migration theory is also consistent with the results obtained by Popovich F et al., who in their study had shown that in children aged 9 to 16 years, the upper labial frenum slightly moved to an apical position from coronal position, while movement in the opposite direction was never detected [24]. The results of this longitudinal assessment were also consistent with the results of the cross-sectional study by Santa Maria C et al., where the children with the most coronal attachment were mostly young [2,24].

As per the reports of Santa Maria C et al., all newborn babies have some degree of superior labial frenal attachment, the majority of which extend approximately half way down the upper gingiva and anterior papilla and which regress as the age advances [2]. Their findings were supported by Delli K et al., who showed evidence from their research that during childhood, this frenum changes in appearance, becoming less prominent with increasing age [25]. But they were unclear as to whether the appearance of the frenum in the newborn population has any correlation with its appearance in childhood and in later life. The developing form of this frenum

over time during childhood reduces the legitimacy of performing preventive procedures on it [25].

## CONCLUSION(S)

Various studies done on upper labial frenal attachments have focused only on its insertion points without taking into account the contour of the undersurface of the entire lip as a whole from which a frenum is thought to originate due to the paucity of randomised controlled trials. Its histology and development have various theories that are yet to be well substantiated in order for it to be a useful indicator of the severity of lip tie.

**Contributive role of various authors in the preparation of this manuscript:** SS-preparation and initial write-up of the manuscript, LD-idea of the manuscript and final write-up of the manuscript, CM-suggestions and modifications to the body of the manuscript, DS, SPR-citation insertions, and arrangement of references.

[Table/Fig-3] is taken with permission for Spreading Smiles Dental Clinic Puducherry, India (courtesy- Dr. Daisy L, owner- "Spreading Smiles Dental Clinic".

## REFERENCES

- [1] Kotlow LA. Diagnosing and understanding the maxillary lip-tie (superior labial, the maxillary labial frenum) as it relates to breastfeeding. *J Hum Lact.* 2013;29(4):458-64. Doi: 10.1177/0890334413491325. Epub 2013 Jul 2. PMID: 23821655.
- [2] Santa Maria C, Aby J, Truong MT, Thakur Y, Rea S, Messner A. The superior labial frenulum in newborns: what is normal? *Glob Pediatr Health.* 2017;4:17718896. Doi: 10.1177/2333794X17718896.
- [3] Ray S, Golden WC, Walsh J. Anatomic Distribution of the Morphologic variation of the upper lip frenulum among healthy newborns. *JAMA Otolaryngol Head Neck Surg.* 2019;145(10):931-38. Doi: 10.1001/jamaoto.2019.2302. Erratum in: *JAMA Otolaryngol Head Neck Surg.* 2019;145(10):983. PMID: 31436823; PMCID: PMC6707021.
- [4] Boutsis EA, Tatakis DN. Maxillary labial frenum attachment in children. *Int J Paediatr Dent.* 2011;21(4):284-88. Doi: 10.1111/j.1365-263X.2011.01121.x. Epub 2011 Feb 23. PMID: 21348902.
- [5] Iwanaga J, Takeuchi N, Oskouian RJ, Tubbs RS. (June 29, 2017) clinical anatomy of the frenulum of the oral vestibule. *Cureus.* 2017;9(6):e1410. Doi: 10.7759/cureus.1410.
- [6] Pompéia Le, Ilinsky Rs, Ortolani Clf, Faltin K Júnior. Ankyloglossia and its influence on growth and development of the stomatognathic system. *Rev Paul Pediatr.* 2017;35(2):216-21. Doi: 10.1590/1984-0462;2017;35;2;00016. PMID: 28977337; PMCID: PMC5496731.
- [7] Priyanka M, Sruthi R, Ramakrishnan T, Emmadi P, Ambalavanan N. An overview of frenal attachments. *J Indian Soc Periodontol.* 2013;17:12-15.
- [8] Henry SW, Levin MP, Tsaknis PJ. Histologic features of the superior labial frenulum. *J Periodontol.* 1976;47: 25-28.
- [9] Edwards JG. A clinical study: The diastema, the frenum, the frenectomy. *Oral Health.* 1977;67:51-62.
- [10] Gartner LP, Schein D. The superior labial frenum: A histologic observation. *Quintessence Int.* 1991;22:443-45.
- [11] Moore KL. *The Developing Human*, 4<sup>th</sup> edn. Philadelphia: WB Saunders Co, 1988.
- [12] Ross RO, Brown FH, Houston GD. Histologic survey of the frena of the oral cavity. *Quintessence Int.* 1990;21:233-37.
- [13] Flinck A, Paludan A, Mattsson L, Holm AK, Axelsson I. Oral findings in a group of newborn Swedish children. *Int J Paediatr Dent.* 1994;4(2):67-73. Doi: 10.1111/j.1365-263x.1994.tb00107.x. PMID: 7748853.
- [14] Bergese F. Research on the development of the labial frenum in children of age 9-12 (in Italian). *Minerva Stomatol.* 1966;15:672-76.
- [15] Jarićzuk Z, Banach J. Prevalence of narrow zone of attached gingiva and improper attachment of labial frena in youths. *Community Dent Oral Epidemiol.* 1980;8:385-86.
- [16] Placek M, Skach M, Mrklas L. Significance of the labial frenum attachment in periodontal disease in man. Part I. Classification and epidemiology of the labial frenum attachment. *J Periodontol.* 1974;45:891-94.
- [17] Mirko P, Miroslav S, Lubor M. Significance of the labial frenum attachment in periodontal disease in man. Part I. Classification and epidemiology of the labial frenum attachment. *J Periodontol.* 1974;45:891-94.
- [18] Kakodkar PV, Patel TN, Patel SV, Patel SH. Clinical assessment of diverse frenum morphology in Permanent dentition. *Internet J Dent Sci.* 2009;7.
- [19] Anubha N, Chaubey KK, Arora VK, Narula IS. Frenectomy combined with a laterally displaced pedicle graft. *Indian J Dent Sci.* 2010;2:47-51.
- [20] Priyanka M, Sruthi R, Ramakrishnan T, Emmadi P, Ambalavanan N. An overview of frenal attachments. *J Indian Soc Periodontol.* 2013;17:12-15.
- [21] Lindsey D. The upper mid-line space and its relation to the labial fraenum in children and in adults. A statistical evaluation. *Br Dent J.* 1977;143:327-32.
- [22] Huang WJ, Creath CJ. The midline diastema: A review of its etiology and treatment. *Pediatr Dent.* 1995;17(3):171-79.
- [23] Standing S: *Gray's anatomy: The anatomical basis of clinical practice.* Elsevier Health Sciences, London; 2015.

[24] Popovich F, Thompson GW, Main PA. The maxillary interincisal diastema and its relationship to the superior labial frenum and intermaxillary suture. *Angle Orthod.* 1977;47:265-71.

[25] Delli K, Livas C, Sculean A, Katsaros C, Bornstein MM. Facts and myths regarding the maxillary midline frenulum and its treatment: a systematic review of the literature. *Quintessence Int.* 2013;44:177-87.

#### PARTICULARS OF CONTRIBUTORS:

1. Assistant Professor, Department of Anatomy, AIIMS Bibinagar, Telangana, India.
2. Senior Lecturer, Department of Oral and Maxillofacial Surgery, Indira Gandhi Institute of Dental Sciences and Research, Puducherry, India.
3. Senior Resident, Department of Anatomy, AIIMS Bibinagar, Telangana, India.
4. Additional Professor and Head, Department of Anatomy, AIIMS Bibinagar, Telangana, India.
5. Senior Resident, Department of Anatomy, AIIMS Bibinagar, Telangana, India.

#### NAME, ADDRESS, E-MAIL ID OF THE CORRESPONDING AUTHOR:

L Daisy,  
Senior Lecturer, Oral and Maxillofacial Surgery, Indira Gandhi Institute of Dental Sciences and Research, Puducherry, India.  
E-mail: drdaisyloyola@gmail.com

#### PLAGIARISM CHECKING METHODS: [\[Jain H et al.\]](#)

- Plagiarism X-checker: May 26, 2021
- Manual Googling: Jul 26, 2021
- iThenticate Software: Aug 07, 2021 (10%)

ETYMOLOGY: Author Origin

#### AUTHOR DECLARATION:

- Financial or Other Competing Interests: None
- Was Ethics Committee Approval Obtained for this study? NA
- Was informed consent obtained from the subjects involved in the study? No
- For any images presented appropriate consent has been obtained from the subjects. Yes

Date of Submission: **May 25, 2021**

Date of Peer Review: **Jul 16, 2021**

Date of Acceptance: **Jul 27, 2021**

Date of Publishing: **Oct 01, 2021**